

## ORIGINAL ARTICLE

# Root Canal Morphology of Human Permanent Mandibular Anterior Teeth in an Indian Population using CBCT.

Kiran Kurumboor<sup>1</sup>, G. S. Tarun<sup>2</sup>, R. Vinay Chandra<sup>3</sup>, V. Vasundhara<sup>4</sup>, C. N. Aruna<sup>5</sup>

## ABSTRACT

The tenets of root-canal treatment are the preparation, cleaning, and sealing of the root canals. An understanding of the variations in root-canal anatomy is necessary by those carrying out treatment. Recognition of a variation when it occurs is the first and most frequent step in completing successful treatment for these teeth. This study was done to evaluate differences in the root and canal configurations of mandibular permanent anterior incisors and canines in an Indian population by means of Cone Beam CT (CBCT) images

**Keywords:** Mandibular anterior teeth morphology, CBCT, Indian population

**How to cite this article:** Kurumboor K, Tarun GS, Chandra RV, Vasundhara V, Aruna CN. Root canal morphology of human permanent mandibular anterior teeth in an Indian population using CBCT. *Int J Oral Care Res* 2018;6(1):S102-106.

**Source of support:** Nil

**Conflicts of interest:** None

## INTRODUCTION

The hard tissue repository of the human dental pulp takes on numerous configurations and shapes. A thorough knowledge of tooth morphology, careful interpretation of angled radiographs, proper access preparation, and a detailed exploration of the interior of the tooth are essential prerequisites for a successful treatment outcome.

Slowey *et al.*<sup>[1]</sup> stated that the root canal anatomy of each tooth has certain commonly occurring characteristics as well as numerous atypical ones that can be road-maps to successful endodontics.

Studies on root canal anatomy have been done using various techniques such as radiography, injecting a

radiopaque contrast medium, clearing technique, direct observation with microscope, three-dimensional (3D) reconstruction, spiral computed tomography (CT), and macroscopic sections. Further methods to determine the root canal morphology include SEM-modified clearing and staining technique, cone-beam CT (CBCT), and micro-CT.

Recently, CBCT has become available for dental offices because of the reduced costs. Unlike conventional CT scans, they have a reduced acquisition time and use lower irradiation doses. Their field of view is limited, but the spatial resolution is very good in all planes. An advantage of the CBCT is that the images can be studied using different representations (multi-planar reformation and 3D surface rendering). They can be rotated in any spatial plane without superimposition of the anatomic structures.

It is a well-established fact that the root canal anatomy varies with races. Some authors concluded that gender plays a role in determining canal morphology and that both gender and ethnic origin should be considered in the pre-treatment evaluation for root canal therapy. In addition, patients of Asian descendants have different canal configurations than those reported in studies dominated by rest of population.

Only very few studies are there on root canal anatomy of mandibular teeth in the Indian population. Hence, this study was undertaken to extensively study the morphology of the mandibular anterior teeth using CBCT technique. The aim of the study is to evaluate the root canal morphology of all human permanent mandibular teeth from mandibular central incisor up to canine in an Indian population using CBCT. Hence, the purpose of the study is to evaluate the root canal morphology of all human permanent mandibular teeth from mandibular central incisor up to mandibular second molars in an Indian population using CBCT.

## Aim

The aim of this study is to evaluate the root canal morphology of all human permanent mandibular teeth from mandibular central incisor up to mandibular second molars in an Indian population using CBCT.

<sup>1</sup>Private Practitioner, <sup>2,4</sup>Senior Lecturer, <sup>3,5</sup>Professor

<sup>1</sup>Root and Crown Dental Care, Thrissur, Kerala, India

<sup>2,4</sup>Department of Conservative and Endodontics, Rajarajeswari Dental college and Hospital, Bengaluru, Karnataka, India

<sup>5</sup>Department of Public Health Dentistry, Rajarajeswari Dental college and Hospital, Bengaluru, Karnataka, India

**Corresponding Author:** Dr. Kiran Kurumboor, Private Practitioner, Root and Crown Dental Care, Thrissur - 680 545, Kerala, India. Phone: +91-9746278911. e-mail: kirankurumboor@gmail.com

## MATERIALS AND METHODS

### Sample Collection

A total of 100 extracted human mandibular teeth comprising of central incisor, lateral incisor, and canine were taken for this study. Teeth with fracture, caries, cuspal fracture, and severe attrition were excluded from the study. The teeth were then stored in formalin, and any attached soft tissue and calculus were removed with an ultrasonic scaler. The storage was carried out as per the OSHA guidelines and regulation.<sup>[2]</sup> The teeth were then mounted vertically on a wax sheet of 4 mm with the buccal surface facing outward for scanning.

### Assessment Protocol

The American Dental Association has recently developed a Digital Imaging and Communications in Medicine (DICOM) standard for use in dentistry. This software was used in this study where the images could be saved in DICOM format.

### Sample Arrangement

The teeth were randomly inserted into foam arches in close contact to each other to simulate their natural alignment in a dental arch. Teeth were randomly arranged on a wax sheet which was folded in to a thickness of 2 mm to mimic soft tissue on the radiographs. A motorized arm and platform with the help of two laser beams provide precise alignment. Bite blocks and

lateral holders provide wax mandible support to which teeth are mounted. All the teeth were scanned by a CBCT scanner with constant thickness of 0.25 mm voxel size. The teeth were viewed in axial, sagittal, and coronal plane. Volume rendering and multiplanar volume reconstruction were performed using the Advantage Windows workstation.

### Parameters assessed

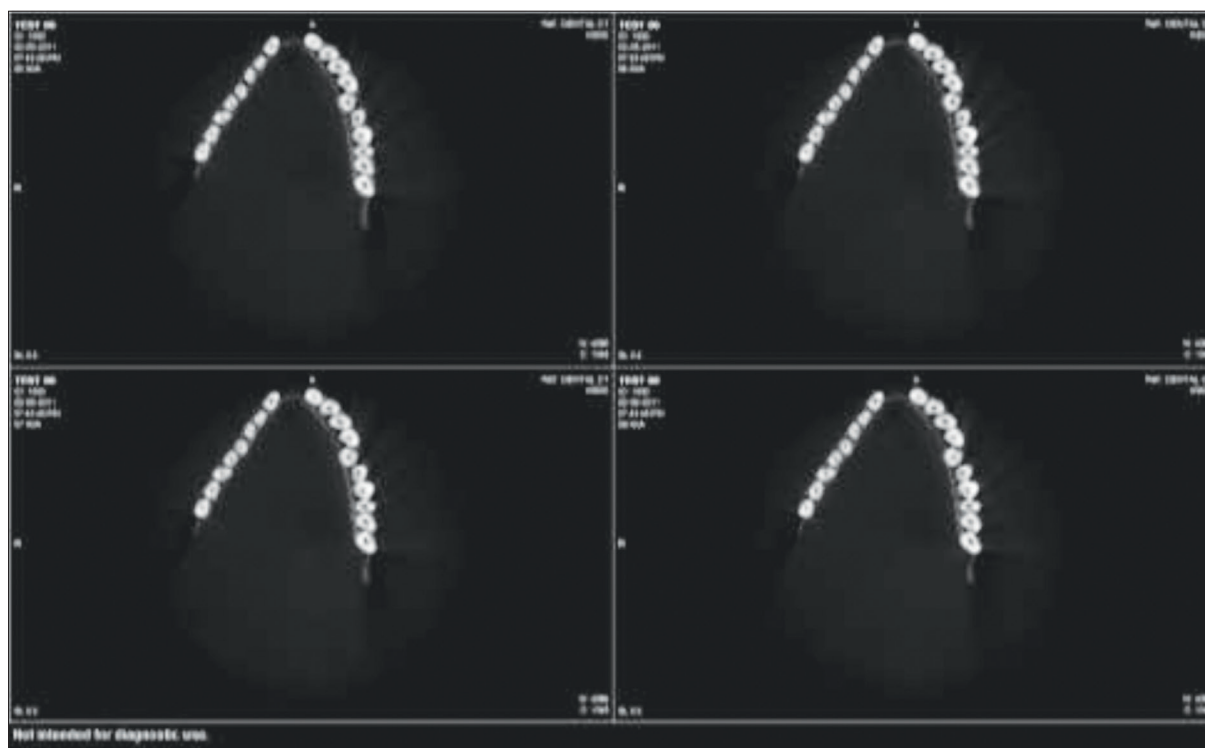
- I. Length of the mandibular anterior teeth.
- II. Internal morphologic measurements.
  - a. Measurement of the distance from incisal edge and the pulp chamber roof in anterior teeth.
  - b. Relation of cementoenamel junction (CEJ) to roof of the pulp chamber in anterior teeth.
- III. Number of roots in mandibular anterior teeth.
- IV. Number root canals in mandibular anterior teeth.
- V. Pattern of root canal morphology in mandibular anterior teeth.

### Assessment Modality

The advent of CBCT technology has paved way for the development of relatively small and inexpensive CT scanners dedicated for use in dentomaxillofacial imaging [Figure 1].

## RESULTS

Tables 1a-e show mandibular central incisors, lateral incisors, and canines.



**Figure 1:** Scanned samples - scout image

**Table 1a:** Number of roots and root canals

Tooth (n=100)	Single root (%)	One canal (%)	Two canal (%)	Three canal
Central incisor	100	89	11	-
Lateral incisor	100	74	11	-
Canine	100	86	14	-

**Table 1b:** Root canal pattern (Vertucci's classification)

Tooth (n=100)	Type I	Type II	Type III	Type IV	Type V	Type VI	Type VII	Type VIII	C-shaped canal
Central incisor	73	1	13	10	3	-	-	-	-
Lateral incisor	67	3	17	8	5	-	-	-	-
Canine	79	3	6	9	1	2	-	-	-

**Table 1c:** Crown/root length

Tooth (n=100)	Crown length	Root length	Overall length
Central incisor	9.28 mm	12.9 mm	22.2 mm
Lateral incisor	8.63 mm	12.83 mm	21.4 mm
Canine	10.3 mm	14.8 mm	25 mm

**Table 1d:** Distance from the incisal edge to roof of the pulp chamber

Tooth (n=100)	Mean (mm)	Standard deviation
Central incisor	4.4171	1.2384
Lateral incisor	4.8516	1.0498
Canine	5.6022	1.2943


**Table 1e:** Relation of CEJ to roof of the pulp chamber

Tooth (n=100)	CEJ coinciding with roof (%)	CEJ above the roof (%)	CEJ below the roof (%)
Central incisor	24	1	75
Lateral incisor	33	-	67
Canine	31	4	65

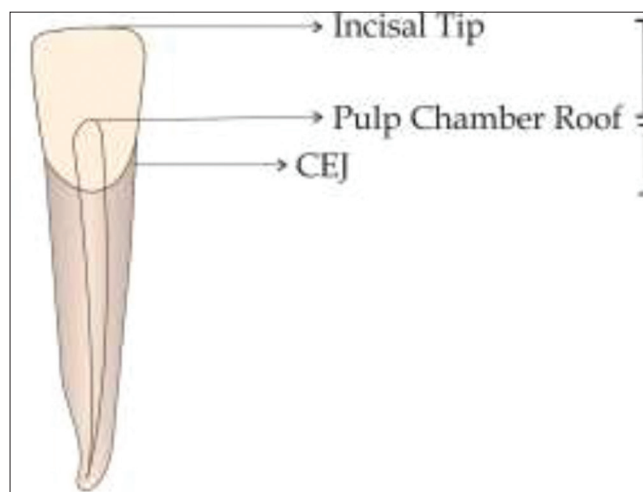
CEJ: Cementoenamel junction

**Morphological Measurements [Tables 1c-e, Figures 2 and 3]**

Figure 2: Cone-beam computed tomography views - coronal, axial, and sagittal



**Figure 2:** Cone-beam computed tomography views - coronal, axial, and sagittal



**Figure 3:** Morphological measurements in mandibular teeth

**DISCUSSION**

Variation in root canal anatomy is common and is considered as a normal phenomenon. For success in endodontic treatment, a thorough understanding of the root canal morphology is necessary.

The studies on root canal anatomy by Hess and Zurcher<sup>[5]</sup> as early as 1924 reported that a root with a graceful, tapering canal and a single apical foramen is an expectation rather than a rule. Vertucci<sup>[18]</sup> in 1984 who classified root canal anatomy broadly into 8 types.

CBCT now provides the clinician with the ability to observe an area in three different planes and thus to acquire 3D information. The combination of sagittal, coronal, and axial CBCT images eliminates the superimposition of anatomic structures.

CBCT scanning or digital volume tomography uses an extraoral imaging scanner to produce 3D scans of the maxillofacial skeleton at a considerably lower radiation dose than conventional CT scanning. CBCT scanning has been shown to be more accurate than digital radiographs in determining root canal systems.

When the root canal configuration deviates from the normal and expected anatomy, it is always difficult for an endodontist to adequately and effectively clean, shape, and obturate it. The awareness of these possible deviations that might occur in the root canal morphology would greatly enhance the quality of treatment.

Many studies have reported that root canal systems vary according to race.<sup>[3,6,7,8]</sup> Literature reveals that very few studies have been done on root canal morphology of teeth in an Indian population. Studies on

morphologic variations have been reported on the mandibular first premolars by Velmurugan *et al.* in 2009,<sup>[4]</sup> mandibular first molar by Reuben *et al.*<sup>[2]</sup> in 2008, and mandibular second molars by Prasanna *et al.* in 2010 on the Indian populations. Hence, this study was undertaken to extensively assess the root canal morphology of all the mandibular teeth.

The overall average length of the mandibular central incisor is 22.2 cm with an average crown length of 9.28 mm and an average root length of 12.9 mm. The mandibular lateral incisor with an average length is 21.4 mm, with the crown length of 8.63 mm and with an average root length of 12.83 mm.

The mean distance from the incisal edge to the roof of the pulp chamber in mandibular central and lateral incisor was 4.41 mm and 4.85 mm, respectively.

The CEJ coincided with the roof of pulp chamber in 24% and 33% coincides with the cases, and it was lower than the roof of pulp chamber in 39 and 33% of the samples, respectively.

Most common root canal pattern in central incisor and lateral incisor was type I pattern (89% and 74%). These results are similar to the results of a previous study done in Turkish population<sup>[9]</sup> but contrary to the results reported by Uma *et al.* who reported that type III pattern was more prevalent. However, in this study, type III pattern was seen only in 13% and 17% of central incisors and lateral incisors, respectively.

In 2010, Boruah and Lalith<sup>[12]</sup> using staining technique reported that the majority of mandibular incisors in north-east Indian population had a single root canal type I (63.75%). Although 36.25% of roots possessed two canals only, 6.25% had two separate apical foramina.

In the present study, the incidence of second canal was found to be only 11%. Madiera and Hetenn have also reported similar incidence of 11.3% of two canals in Turkish population, whereas Miyashita M *et al.* in 1997 reported 15% (1085 samples) of two canals in mandibular incisors in Japanese population. Our result is contrary to the results reported by Kartal and Yanicoglu<sup>[10]</sup> (43%) and Benjamin and Dowson<sup>[11]</sup> (41.4%) who had reported very high incidence of two canals.

## CONCLUSION

Overall mandibular central incisors (73%), lateral incisors (67%), and canines (78%) - majority of samples displayed type I configuration in Indian population. Two canals were detected in 11% of the both incisors and 14% in canines. Type III pattern was seen in 13% and 17% of the central and lateral incisors. 6% canines had type III configuration and 3% had type II. CEJ was commonly found below the pulp chamber (75%, 67%, and 65%).

## Mandibular Canine

The average length of mandibular canines in our study was found to be 25 mm. This is in accordance with the result reported by Pucci and Reig<sup>[19]</sup> in 1944. Distance from the incisal edge to the pulp chamber roof showed a mean value of 5.6 mm. This distance could act as a guide during access cavity preparation. In 31% of the samples studies, the pulp chamber roof coincided with CEJ. CEJ was lower than the roof of pulp chamber in 65% of samples and, in 4% of the cases, above the pulp chamber. Hence, CEJ cannot be used as a guide for the assessment of depth of pulp chamber.

All the samples were single rooted. In the present study, type I pattern (79%) was the most common followed by type IV (9%). This result is in accordance with the earlier in study done by Sikri *et al.* in 2003 in Indian population.

2% of samples showed type VI pattern and 1% showed type V pattern. The existence of two canals was seen in 14%. This is in agreement with results of Hession<sup>[13]</sup> (11%), Green<sup>[14]</sup> (13%), and Koffe *et al.*<sup>[15]</sup> (13.75%). It is, however, higher than the result of Bellizzi and Hartwell<sup>[16]</sup> (4.11%) and Ingle *et al.*<sup>[17]</sup> (6%) but lower than the result of Vertucci<sup>[18]</sup> (22%)

## CONCLUSION

CBCT allows identification of anatomic features and variations of the root canal system. Therefore, within the limitations of this study, it can be concluded that:

Mandibular central incisors (73%), lateral incisors (67%), and canines (78%) - majority of samples displayed type I configuration. Two canals were detected in 11% of the both incisors and 14% in canines. Type III pattern was seen in 13% and 17% of the central and lateral incisors. 6% canines had type III configuration and 3% had type II. CEJ was commonly found below the pulp chamber (75%, 67%, and 65%).

In a clinical scenario, to treat and retreat, dentists should be aware of the possible existence of additional canals and variations in canal anatomy before initiating endodontic treatment.

## REFERENCES

1. Slowey RR. Root canal anatomy. Road map to successful endodontics. *Dent Clin North Am* 1979;23:555-73.
2. Reuben J, Velmurugan N, Kandaswamy D. The evaluation of root canal morphology of the mandibular first molar in an Indian population using spiral computed tomography scan: An *in vitro* study. *J Endod* 2008;34:212-5.
3. Hess W, Zurcher E. The Anatomy of the Root Canals of Teeth of the Permanent and Deciduous Dentition. New York: William Wood and Co.; 1925.
4. Vertucci FJ. Root canal anatomy of the human permanent

- teeth. Oral Surg Oral Med Oral Pathol 1984;58:589-99.
5. Walker RT. Root canal anatomy of mandibular first premolars in a Southern Chinese population. Endod Dent Traumatol 1988;4:226-8.
  6. Haddad GY, Nehme WB, Ounsi HF. Diagnosis, classification, and frequency of C-shaped canals in mandibular second molars in the Lebanese population. J Endod 1999;25:268-71.
  7. Weine FS, Hayami S, Hata G, Toda T. Canal configuration of the mesiobuccal root of the maxillary first molar of a Japanese sub-population. Int Endod J 1999;32:79-87.
  8. Sert S, Bayirli GS. Evaluation of the root canal configurations of the mandibular and maxillary permanent teeth by gender in the Turkish population. J Endod 2004;30:391-8.
  9. Velmurugan N, Sandhya R. Root canal morphology of mandibular first premolars in an Indian population: A laboratory study. Int Endod J 2009;42:54-8.
  10. Çalışkan MK, Pehlivan Y, Sepetçioğlu F, Türkün M, Tuncer SS. Root canal morphology of human permanent teeth in a Turkish population. J Endod 1995;21:200-4.
  11. Boruah L. Root canal morphology of permanent mandibular incisors in a North East Indian population-*in vitro* study using a root canal staining technique. Quintessence Int Endo 2010;4:274-8.
  12. Kartal N, Yanikoğlu FC. Root canal morphology of mandibular incisors. J Endod 1992;18:562-4.
  13. Benjamin KA, Dowson J. Incidence of two root canals in human mandibular incisor teeth. Oral Surg Oral Med Oral Pathol 1974;38:122-6.
  14. Pucci FM, Reig R. Conductors radicularis. In: Editorial Medico-Quirurgica. Vol. 1. Buenos Aries: Argentina Medical Press; 1944.
  15. Hession RW. Endodontic morphology. II. A radiographic analysis. Oral Surg Oral Med Oral Pathol 1977;44:610-20.
  16. Green D. Double canal in single roots. Oral Surg Oral Med Oral Pathol 1973;35:689-96.
  17. Kaffe I, Kaufman A, Littner MM, Lazarson A. Radiographic study of the root canal system of mandibular anterior teeth. Int Endod J 1985;18:253-9.
  18. Bellizzi R, Hartwell G. Clinical investigation of *in vivo* endodontically treated mandibular anterior teeth. J Endod 1983;9:246-8.
  19. Ingle JL, Backland LK, Brveridge EE, Glick DH, Hoskinson AE. Modern endodontic therapy. In: Ingle JL, Backland LK, Taintor FJ, editors. Endodontics. 5th ed. Philadelphia, PA: Lea and Febiger; 2002. p. 1-23.